

Case Study #1

Recurrent Abdominal Pain – Gastritis and Polyp in Fundus

A 52-year-old female patient presented with recurrent abdominal pain for 3 months.

History:

No medical history.

Magnetically Controlled Video Capsule Endoscopy (MCCE) of the stomach was performed to evaluate her condition.

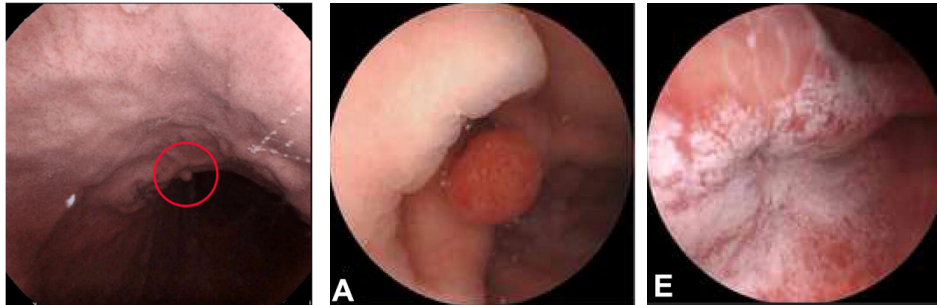
Additional tests performed:

- H. pylori bacterial test was ordered

Findings:

H. pylori test was negative. The stomach was clean and completely visualized.

Gastritis and a polyp in the fundus were visualized¹ – see pictures



Outcome:

This patient was diagnosed with chronic atrophic gastritis. In addition to the gastritis, a polyp in the fundus was visualized and an EGD was performed to remove the polyp.

PPI's were prescribed for treatment of the chronic atrophic gastritis.

No additional information or follow up is available.

Conclusion:

MCCE turned out to be a patient-friendly additional method to visualize the gastric mucosa.

¹ Jiang X, et al. Standardized examination procedure of magnetically controlled capsule endoscopy. VideoGIE 2019;4(6):239-43