

Case Study #3

A 54-year-old male presented with abdominal pain

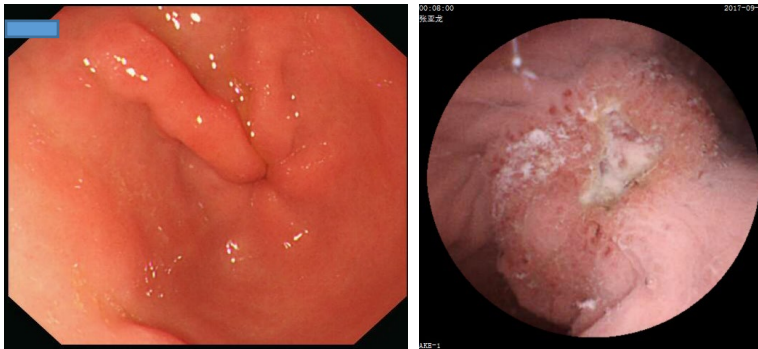
History:

Family history of gastric cancer, therefore, he was classified as a high-risk patient.

In August 2011, a conventional EGD was negative (see picture: left side). He refused to undergo a re-examination by EGD due to fear of pain. MCCE of the stomach was performed to evaluate the mucosa.

Findings:

Stomach was clean and completely visualized. MCCE indicated gastric cancer¹ (right picture).

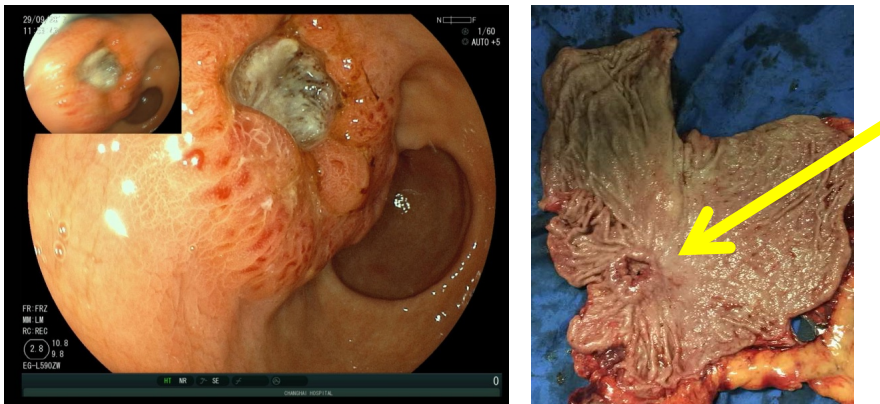


Negative EGD in 2011

MCCE in 2017

Outcome:

Suspected cancer was confirmed by EGD / biopsy (left) and a gastrectomy was performed (right).



Conclusion:

After sharing the MCCE images, patient accepted to undergo an EGD incl. biopsy even though he denied in the beginning. MCCE clearly revealed the gastric cancer.

¹ By courtesy of Prof. Liao in Shanghai Hospital, China